



**PATIENT**

Lucie Day

**SPECIES**

Feline

**BREED**

DLH

**SEX**

Female Spayed

**AGE**

14 years

**WEIGHT**

9lbs

**INTERPRETED BY**

Maggie Machen Lamy,  
DVM, DACVIM  
(Cardiology)

**IMAGING PERFORMED BY**

Lauren Kuzimski, DVM

**HOSPITAL NAME**

Animal Emergency  
Hospital Deland

**REFERRING VET**

Dr. Lauren Kuzimski

**INVOICE**

46692

**DATE**

2/4/26

**PRESENTING CLINICAL SIGNS**

History: Presented with coughing fits for a while; started on steroids last week for asthma. Yesterday, breathing worsened substantially. Concern for CHF; started on Lasix but worsened overnight.  
-Abnormal PE/Chem/CBC/UA Results: CBC. leukocytosis with neutrophilia, monocytosis, HCT 52.8%, thrombocytopenia (patient was not an easy blood draw due to concurrent issues - platelet clump noted) Chemistry. BUN 64.6, phosphorus 8.1, calcium 8.3, glucose 284, ALT 339 EPOC. BE -7.3, sodium 147, potassium 3.5, iCa 1.17, BUN 54, glucose 282, HCT 54%. Elevated BNP. BP: 119mmHg.

**RADIOGRAPHIC FINDINGS** \*NOTE: Images submitted for supplemental cardiac information only.  
Cardiomegaly with concern for CHF.

**ELECTROCARDIOGRAPHIC FINDINGS** \*Note: Single lead ECGs are evaluated as a rhythm strip. Morphology/MEA cannot be definitively commented on.

A single lead ECG is available; 25mm/s, 20mm/mV. The average heart rate is 140bpm. The rhythm is sinus in origin, with a p for every QRS complex and vice versa. The P and QRS morphologies are positive. The PR interval is prolonged. No ectopic beats, pauses or other dysrhythmias observed.  
ECG diagnosis: Sinus bradycardia v other.

**ECHOCARDIOGRAM FINDINGS**

2D, m-mode, color flow and doppler imaging is available. The left ventricular wall is asymmetric with a significant septal hypertrophy contrasting a normal free wall. . There is a mildly hyperechoic endocardium consistent with fibrosis. Intact systolic function. There is papillary muscle hypertrophy and remodeling. The left atrium is severely dilated with a horizontal component. No smoke; no obvious thrombus. The right atrium is mildly dilated. The right ventricle is also hypertrophied. The mitral valve is normal, although not extensively visualized. Trace central MR. Scant pericardial and pockets of pleural effusion. No obvious cardiac masses.

**CARDIAC CHART**

FELINE CARDIAC PARAMETERS	BODY WEIGHT (kg)	HR (BPM)	IVSd (cm) (Moise, Pipers)	LVIDd (cm) (Moise, Pipers)	LVWd (cm) (Moise, Pipers)	FS (%)	EF (%)
<b>NORMAL PARAMETER</b>	-----	150-240	0.35-0.55	<2 (mean 1.5)	3.5-0.55	35-67	80-100
<b>PATIENT</b>	4.1		0.70	1.0	0.48	47	90
FELINE CARDIAC PARAMETERS	LA/AO (Boon)	LA/AO HEART BASE (Swe) (Abbott)	LA 2D short axis Base view (cm) (Abbott)		LVOT VEL (m/s)	RVOT VEL (m/s)	E max (m/s)
<b>NORMAL</b>	<1.5	<1.3	<1.2		<1.6	<1.3	<0.9
<b>PATIENT</b>	NM	1.9	1.7		NM	NM	NM
*Note: All measurements based upon multi-modal images and methods. An average value is reported. Adapted from June Boon, Veterinary Echocardiography, 1998 Abbott J & MacLean H JVIM 2006;20: 111-119, Moise et al. Am J Vet Res 47:1476, 1986. Pipers et al. Am J Vet Res 40:882, 1979.							



## PATIENT

Lucie Day

## SPECIES

Feline

## BREED

DLH

## SEX

Female Spayed

## AGE

14 years

## WEIGHT

9lbs

## INTERPRETED BY

Maggie Machen Lamy,  
DVM, DACVIM  
(Cardiology)

## IMAGING PERFORMED BY

Lauren Kuzimski, DVM

## HOSPITAL NAME

Animal Emergency  
Hospital Deland

## REFERRING VET

Dr. Lauren Kuzimski

## INVOICE

46692

## DATE

2/4/26

## INTERPRETATION OF THE FINDINGS & FURTHER RECOMMENDATIONS

HCM is a rule out diagnosis for LV hypertrophy once a patient is confirmed euthyroid and normotensive. Both should be considered in this case. Regardless, the left atrium is severely enlarged, indicating high risk for spontaneous CHF and/or blood clot events. The right heart is also affected to a slightly lesser extent. No obvious additional issues are identified. It is important to note this is not considered a complete evaluation and small abnormalities may have been missed.

Of some concern, the resting HR is relatively low for a patient in hospital. Assuming the patient was not sedated, further workup is advised. The ECG is suggestive of P waves and a sinus origin; however, the PR interval is prolonged. An ancillary issue such as an indioventricular rhythm is possible. If the HR does not stimulate, this may reflect a conduction issue, which warrants further evaluation. Findings are speculative in the absence of a six-lead tracing, and reassessment once the patient is stabilized is recommended.

These findings certainly support a diagnosis of CHF in this case. It is unclear if some component was due to use of steroids; however, at this point the differentiation is somewhat academic. Full cardiac support should be continued going forward with hospitalization until stable. A thoracocentesis should be considered if necessary.

If able to be stabilized, the mean survival time for cats with CHF is 8-12 months, however most cats are able to maintain a good quality of life on medications. Patient will always be at high risk for recurrent episodes of CHF and development of blood clots in the future.

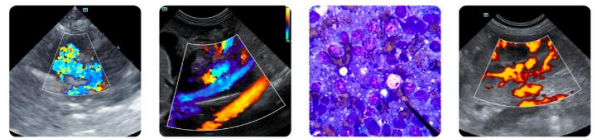
Monitoring of sleeping breathing rates at home is recommended as the best way to screen for recurrent CHF at home. Avoid anesthesia, steroids and fluid therapy unless absolutely necessary in the future.

## PLAN

Consider a thoracocentesis if needed. Continue injectable Lasix dose/hospitalization. Discharge on the following: administer Lasix 1-2mg/kg PO q12h. Administer Pimobendan 1.25mg PO q12h. If able, administer blood thinner Clopidogrel (Plavix) 75mg tablets; give ¼ tab orally once daily (NOTE: this medication is very bitter on the cut edges). Baseline T4 and BP recommended with monitoring every 6 months.

Monitor renal values, BP and recheck ECG in 1-2 weeks then every 3-4 months lifelong. If doing well and BP is > 130mmHg, institute ACE-I 0.5,g/kg PO q12h. If the HR is persistently low, referral for a six-lead tracing may be necessary.

A recheck echocardiogram is recommended in 6 months to assess progression.



## PATIENT

Lucie Day

## SPECIES

Feline

## BREED

DLH

## SEX

Female Spayed

## AGE

14 years

## WEIGHT

9lbs

## INTERPRETED BY

Maggie Machen Lamy,  
DVM, DACVIM  
(Cardiology)

## IMAGING PERFORMED BY

Lauren Kuzimski, DVM

## HOSPITAL NAME

Animal Emergency  
Hospital Deland

## REFERRING VET

Dr. Lauren Kuzimski

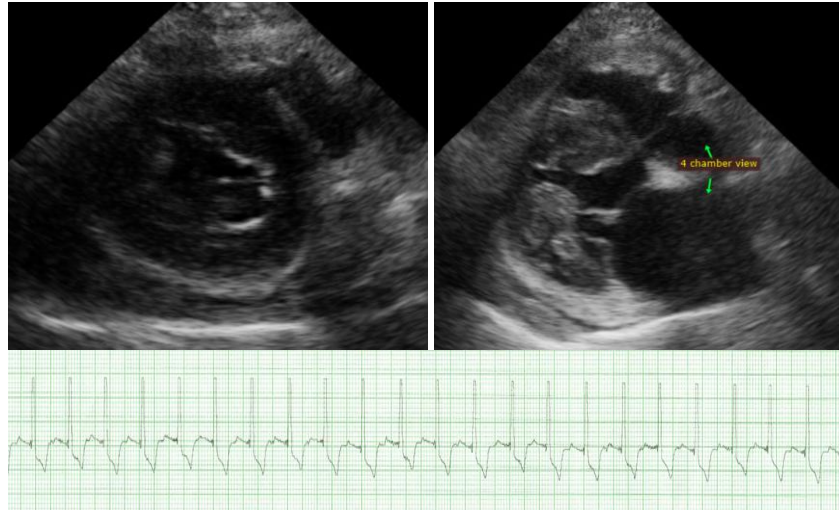
## INVOICE

46692

## DATE

2/4/26

## IMAGES



The information and recommendations provided are based on the images presented by the referring veterinarian. No evaluation can be communicated regarding pathology that was not visible in the image/video clips provided.

Thank you for this referral. This report was generated using transcription software, and minor dictation errors may be present. If the clinical or image interpretation does not parallel your findings or if I can be of any further assistance, please contact me.

**Maggie Machen Lamy, DVM**  
**Diplomate of the American College of Veterinary Internal Medicine (Cardiology)**  
info@sonopath.com